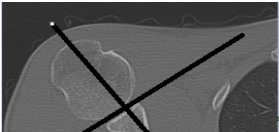
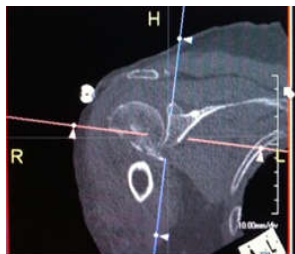

# Shoulder 64 GE

Indications	Pain, swelling, fall, mva, trauma				
Diagnostic Task	Detect fractures, dislocations, arthritis				
Scan mode	Helical				
Position/Landmark	Head first-Supine S100-I230				
Topogram	AP 120kV 20mA Lat 120kV 80mA				
kVp/Reference mass	120kv Auto mA (100-700)				
Rotation time/pitch	0.9/0.516:1				
Detector Configuration	64x.625				
Table Speed/Increment	20.62				
Dose reduction	Noise Index 22.10				
Allowed CTDI ranges*	7mGy-50mGy				
XR29 Dose Notification value	50mGy				
Helical Set	recon	body part	thickness spacing	algorithm	recon destination
	1	shoulder bone	.625mmx .625mm	bone	pac
	2	soft tissue	.625mmx.625mm	standard	mpr 3d
	3	shoulder	2.5mmx 2.5mm	standard	pac
	4	sag bone	2mmx2mm	bone	pac
	5	coronal bone	2mmx2mm	bone	pac
	6	sag soft tissue	2mmx2mm	standard	pac
	7	coronal soft tissue	2mmx2mm	standard	pac
Scan Start/end location	1cm superior to AC joint				
	1cm inferior to scapula				
DFOV	25 cm				
	decrease appropriately				
3D Technique Used	do 3d spin with recon 2- 20 images rotate externally-if fracture seen				
IV contrast volume/type	100ml -isovue 370- if needed for soft tissue infection or mass				
Scan delay	90seconds-Performed as directed by a the supervising radiologist				
	Affect arm down by side with palm up				
	Contralateral arm above head				
	If there is a shoulder prosthesis, scan to include the distal end of the humeral component.				

Use an axial image at mid glenoid level to reformat sag and coronal reformats 2mmx2mm



Use coronal image at the mid glenoid level to reformat sag image 2mmx2mm

