

Female Pelvis Ultrasound Protocol

Reviewed By: Spencer Lake, MD

Last Reviewed: February 2020

Contact: (866) 761-4200, Option 1

****NOTE for all examinations:**

1. **If documenting possible flow in a structure/mass, all color/Doppler should be accompanied by a spectral gate for waveform tracing**

****EXCEPTION: Fibroids do not need to have spectral tracing****

2. **CINE clips to be labeled:**

-MIDLINE structures: “right to left” when longitudinal and “superior to inferior” or “fundus to cervix” when transverse

-RIGHT/LEFT structures: “lateral to medial” when longitudinal and “superior to inferior” when transverse

****each should be 1 sweep, NOT back and forth****

****Kidneys do not need to be routinely imaged unless there is a uterine anomaly detected****

Transabdominal: Full Bladder

-Attempt to visualize all structures TA

Transvaginal: Empty Bladder

-In a majority of cases, TV imaging will be needed to visualize any structures not adequately visualized TA. When the sonographer believes structures to be optimally visualized transabdominally, clearance must be given by the radiologist prior to release of the patient.

- TV imaging should not be performed if declined by the patient, in pediatric/not sexually active patients, or in patients who have had a vaginal delivery within 6 weeks (or discussed with radiologist).

NOTE:

-Most examination will be TA & TV

-TV only can be performed if ordered by clinician

HOWEVER, if only TV is ordered and some anatomy is sub-optimally visualized or not seen at all, add (limited) TA to attempt visualization of missing structures

-Please comment on worksheet which measurements are to most accurate based on real-time scanning (TA or TV).

Uterus:

General: See below for list of required views (STILL and CINE)

-Size:

→ Length in sagittal from fundus to external os of cervix (include cervix)

→ The length can be measured as a straight line from the fundus to the external os (if possible) or can be measured as separate linear measurements (to be added together) from the fundus along the endometrial lining to the internal os and along the endocervical canal from internal os to external os in flexed uteri.

→ The uterus trace function utilizing linear measurements with pivot points can be used if available; please do not use free-hand tracing.

→ AP in same sagittal view as length (perpendicular to length)

→ Width in transverse view

→ Provide volume measurement

-Orientation: document anteverted/retroverted (cervix relationship to vagina) and anteflexed/retroflexed (uterus relationship to cervix)

-Evaluate morphology: *see end of document for detailed comments regarding uterine morphology*

→ If anomaly is present, document kidneys

→ Attempt to assess if there are 2 separate cervixes

→ If machine is capable, attempt 3D

→ Coronal CINE, as below

Myometrium: See below for list of required views (STILL and CINE)

-Evaluate for fibroids or diffuse heterogeneity (adenomyosis)

-Measure up to 5 *most significant* fibroids, draw on worksheet diagram. Assess significance as below:

→ Document location in uterus (fundus, body, lower uterine segment, cervix; right, left)

→ Document location within myometrium (intracavitary, submucosal, intramural, subserosal, pedunculated)

→ “Significant” fibroids:

(1) Submucosal

(2) Follow-ups

(3) Unusual appearance

(4) Largest

*If all are typical *intramural or subserosal*, just select the 3 largest*

-Evaluate subendometrial region for cysts or poor delineation between myometrium and endometrium

-Document C-section scar if present

Endometrium: See below for list of required views (STILL and CINE)

-Thickness

→Thickest part of the endometrium should be measured perpendicular to its longitudinal plane in the AP diameter from echogenic to echogenic border

→Adjacent hypoechoic myometrium and fluid in the cavity should be excluded.

→If there is fluid, measure bilayer thickness excluding fluid

→ If endometrium is difficult to discern, adjust focal zone, depth/penetration, harmonics (often off will help)

-Evaluate for focal thickening or intraluminal mass

→ If any abnormality is detected, document presence of flow (color AND spectral Doppler)

-NOTE: If mass is identified (any indication) or abnormal bleeding (any age), add ZOOMED in CINEs (as below)

Cervix: See below for list of required views (STILL and CINE)

-Assess morphology, presence of intraluminal fluid

-Provide images of Nabothian cysts: greyscale and color

-Document any abnormal thickening or mass

-Assess for color; if present, add spectral

-CINEs longitudinal and transverse (as below)

REQUIRED IMAGES: UTERUS

STILL

GENERAL UTERUS/MYOMETRIUM

-Longitudinal greyscale (at least 5): far right (should see some adnexa), mid-right, midline, mid-left, far left (should see some adnexa)

-Transverse greyscale (at least 4): high fundal (should see external contour), fundal, mid-body, lower-uterine segment

ENDOMETRIUM

-ZOOMED in representative longitudinal and transverse greyscale and color images:

-If color is detected, add spectral to demonstrate waveform

CERVIX

- Representative longitudinal and transverse images greyscale and color
 - If color is detected, add spectral to demonstrate waveform

CINE: ALL female pelvis US should have at least TWO CINEs regardless of appearance or indication

GENERAL OVERVIEW:

- TV longitudinal and transverse through entire uterus
 - TA if TV not performed or uterus seen better TA
 - Multiple clips as necessary depending on uterine size and pathology

ADDITIONAL CINES, required and optional:

REQUIRED:

1. Uterine anomaly:

→ True coronal to uterus

2. Endometrial abnormality seen, regardless of indication (i.e., polyp, carcinoma, possible retained products, focal finding, etc.):

→ ZOOMED in *transverse and longitudinal* greyscale centered on endometrium

→ ZOOMED in color (*best plane*) centered on endometrium

3. Abnormal bleeding in any age (including r/o RPOC) and NO abnormality identified at time of scanning:

→ ZOOMED in *transverse and longitudinal* greyscale centered on endometrium

4. Cervical abnormality (excluding typical Nabothian cysts):

→ZOOMED in *transverse and longitudinal greyscale* centered on cervix

→ZOOMED in color (*best plane*) centered on cervix

OPTIONAL, if whole uterus CINEs are inadequate:

1. Fibroids:

→ CINEs as necessary to show fibroid *location in myometrium and relationship to endometrium*

→ NOTE: Add TA if that better demonstrates findings

2. Incidental endometrial findings (including IUD, subendometrial cysts, general/diffuse heterogeneity, other nonspecific findings, etc.):

→ZOOMED in CINE centered on endometrium

→Add color as necessary

3. Technologist discretion

→Add other CINE as necessary

Ovaries:

-Representative longitudinal and transverse views

-Measure size and document volume

-Document abnormalities:

For any mass that is not a simple cyst or non-complex involuting follicle:

→ Assess for color; if present, add spectral

→ CINE TV longitudinal and transverse (TA if TV not done or TA better shows abnormality)

NOTE: Normal ovaries do not require CINE.

-DOPPLER: Attempt to document arterial and venous waveforms for each ovary on all examinations

→ Provide separate tracings for each arterial and venous waveform (i.e., not on the same image)

→ Please spend extra time documenting both venous and arterial waveforms if the indication is rule out torsion or the ovary is abnormal.

NOTE, formal DUPLEX order/charge: must provide adequate documentation of waveforms or reason for difficulty if unable to provide adequate images

Adnexa, including fallopian tubes (if seen):

-Survey both adnexa: greyscale and color Doppler

-Provide representative images of both adnexa: greyscale and color Doppler

-Evaluate for abnormalities and document relationship to ovary

-If abnormality is detected, including simple-appearing para-ovarian cyst and hydrosalpinx

→ Document size, position, shape and relationship to ovaries and uterus

-Attempt to include ovary/other pelvic structures to demonstrate relationship between adnexal finding and other anatomy

→ Assess color; if present, add spectral

→ CINE TV longitudinal and transverse that include mass and adjacent pelvic structures (TA if TV not done or TA better shows abnormality)

-If near ovary, add CINE with gentle abdominal pressure to show structures moving together or separate from ovary

NOTE: Normal adnexa do not require CINE unless examination is to rule out ectopic pregnancy and no IUP present (IUP = at least gestational sac + yolk sac) – as per First Trimester OB protocol

Cul-de-Sac:

-Evaluate for presence of fluid

-Document amount of fluid and location: trace, mild, moderate, large

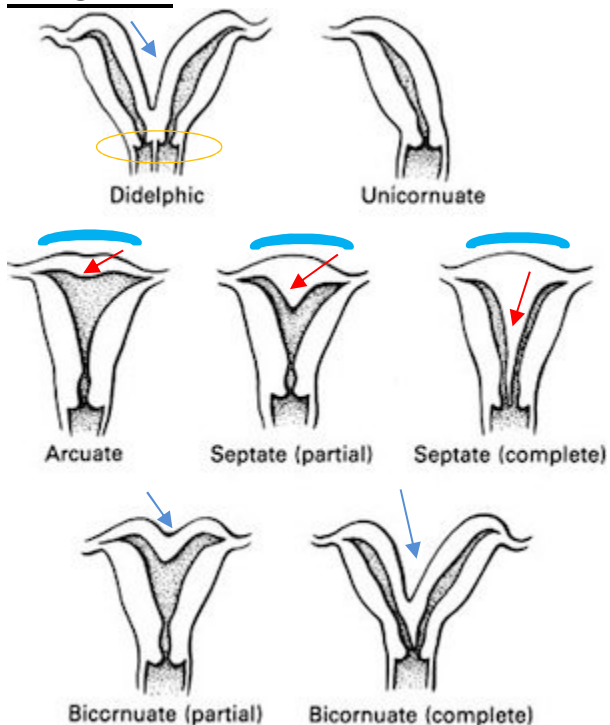
-If = > moderate, evaluate Morrison's pouch for extent of fluid

-Evaluate for mass

-Assess color; if present, add spectral

UTERINE MORPHOLOGY

DIAGRAM



External contour

- Convex, flat or indented < 10 mm = arcuate or septate
Endometrium concave < 10 mm = arcuate
- ↗ Endometrium concave > 15 mm = septate
Endometrium concave 10-15 mm = arcuate vs. septate
- ↘ Concave > 10 mm = bicornuate or didelphys

COMMENTS:

→ **Arcuate** morphology is a normal variant that requires no treatment and has no effect on fertility

-Appearance: Mild indentation of the fundal endometrium with smooth overlying external uterine contour.

→ **Septate** configuration is a uterine anomaly that may require surgical treatment and has potential significant effect on fertility (anomaly most associated with spontaneous first trimester abortion)

-Appearance: Significant indentation of the fundal endometrium with smooth overlying contour

-Septum may continue into the endometrial canal, cervix and vagina

-Septum may be fibrous or muscular (looks like myometrium)

It is very important to differentiate arcuate morphology from true septate configuration as these entities have very different effects on fertility and clinical management

→ **Bicornuate**: indented outer contour (>10 mm) with 2 separate uterine horns that join at some point

-Bicornuate bicollis = 2 cervices (difficult to differentiate from didelphys uterus)

→ **Didelphys**: indented outer contour (>10 mm) with 2 *widely* divergent separate uterine horns that do not join

-Always 2 separate cervices

FOLLICULAR COUNT ULTRASOUNDS

(ordered by fertility medicine)

The following images are documented in an ovarian folliculogram by transvaginal ultrasound. The patient must have had a documented complete pelvic ultrasound within the last 6 months; if not, one will be performed at first visit, then subsequent exams will be limited to areas of interest. In particular instances these images may not all be obtained due to body habitus, agitation, semi-full bladder, and/or overlying bowel gas. This is a limited exam for endometrium and ovaries only, known pathology need not be reevaluated.

Due to limited insurance coverage for fertility related studies with many insurance companies, patient will be required to sign an insurance waiver for each follicular ultrasound performed.

The timing and frequency of the exams will be determined by the referring provider.

Documentation required for worksheet will include

- Endometrial thickness
- Endometrial morphologic appearance (trilaminar or solid)
- Right ovarian antral follicle count (number of follicles 2-10mm)
- Mean value of each right ovarian follicle over 10mm (measured in 2 dimensions at right angles)
- Left ovarian antral follicle count (number of follicles 2-10mm)
- Mean value of each left ovarian follicle over 10mm (measured in 2 dimensions at right angles)

Images

- Sagittal endometrium with and without measurement
- Transverse right ovary superior/anterior.
- Transverse right ovary mid with and without measurements.
- Transverse right ovary inferior/posterior.
- Sagittal right ovary lateral.
- Sagittal right ovary mid with and without measurements.
- Sagittal right ovary medial.

- Right ovary with color Doppler.
- Minimum one cine clip of ovary in sagittal and/or transverse as needed to demonstrate overall follicular appearance.
- Transverse left ovary superior/anterior.
- Transverse left ovary mid with and without measurements.
- Transverse left ovary inferior/posterior.
- Sagittal left ovary lateral.
- Sagittal left ovary mid with and without measurements.
- Sagittal left ovary medial.
- Left ovary with color Doppler.
- Minimum one cine clip of ovary in sagittal and/or transverse as needed to demonstrate overall follicular appearance.

At the conclusion of the exam, please call a body radiologist to discuss the case and assign it to him/her.