

# MSK CT PROTOCOLS

**Protocols** had been adapted from Thomas Jefferson University Musculoskeletal CT Protocols in 2014 with subsequent modifications.

Please contact Dr. George Wang (253-761-4200 or [gwang@tranow.com](mailto:gwang@tranow.com)) for questions and concerns.

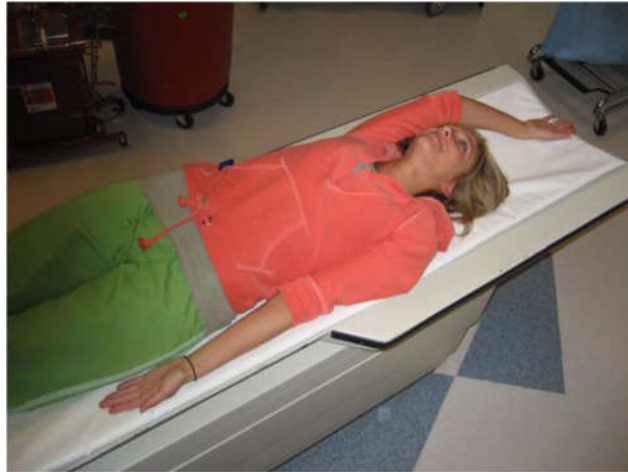## Table of Contents

ROUTINE SHOULDER CT .....	3
ROUTINE ELBOW CT.....	5
Routine Wrist/Hand CT .....	7
ROUTINE BONE PELVIS CT .....	9
ROUTINE BONE HIP CT.....	11
ROUTINE SACROILIAC CT.....	14
ROUTINE KNEE CT.....	17
ROUTINE FOOT/ANKLE/DISTAL TIBIA CT.....	19
Ankle/hindfoot.....	20
Fore/midfoot.....	21
MSK LONG BONE/EXTREMITY CT .....	23
MSK SOFT TISSUE CT.....	24
MSK CT ARTHROGRAM.....	25
METAL PROTOCOL .....	26
BONE LENGTH CT SCANOGRAM.....	27

## ROUTINE SHOULDER CT

### Positioning

- Pt supine
- Affect arm by side with palm up
- Contralateral arm above head.



### Coverage

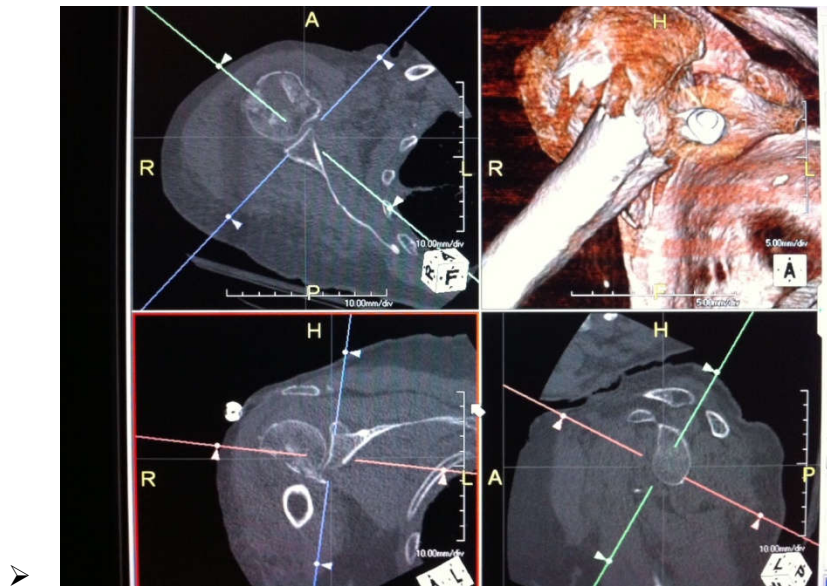
- From above AC joint to the bottom of the scapula.
- *If there is a shoulder prosthesis, scan to include the distal end of the humeral component.*
- Field of view (FOV) just wide enough to include entire scapula and proximal humerus.

### Collimation

- 0.625 mm

### Reformats

- Orient coronal reformats using axial image at the mid glenoid level. Adjust coronal reformats plane to be perpendicular to the glenoid articular surface (green line below, top left box).
- Orient sagittal reformats using coronal reformat image at the mid glenoid level. Adjust sagittal reformats plane to be parallel to the glenoid articular surface (blue line below, bottom left box).



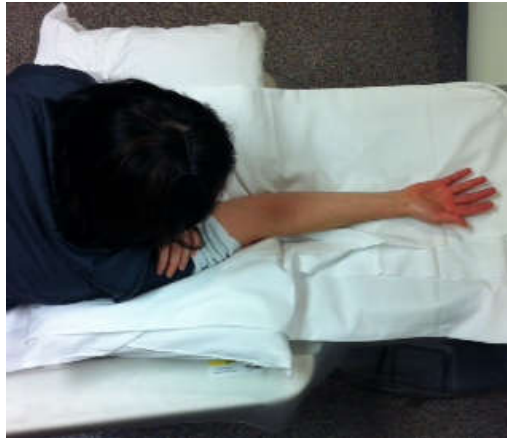**Send only these images**

1. Scout.
2. Source axial images with bone algorithm 0.625 mm.
3. Source axial images with soft tissue algorithm 2 mm.
4. Coronal and sagittal reformats with bone algorithm 2 mm.
5. Coronal and sagittal reformats with soft tissue algorithm 2 mm.
6. 3D MIP reformats at referral's request or if you see obvious fracture.

## ROUTINE ELBOW CT

### Positioning

- Patient prone
- Arm of concern above head with elbow extended
- Palm up



### Coverage

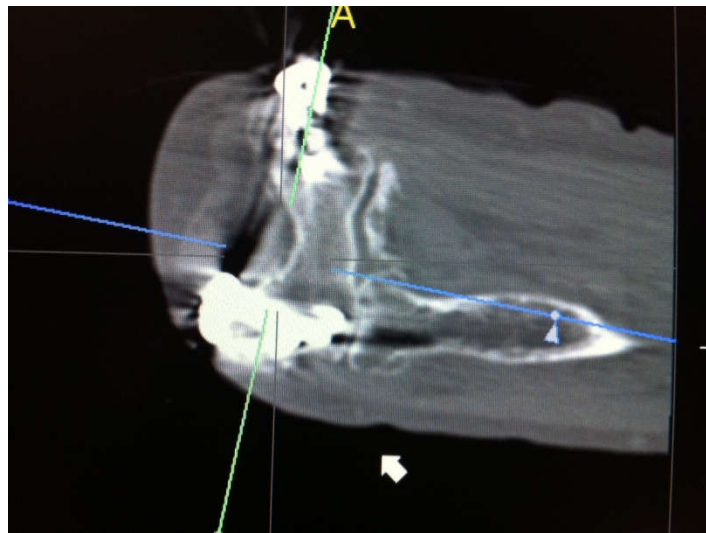- From distal humeral metadiaphysis to the radial tuberosity.

### Collimation

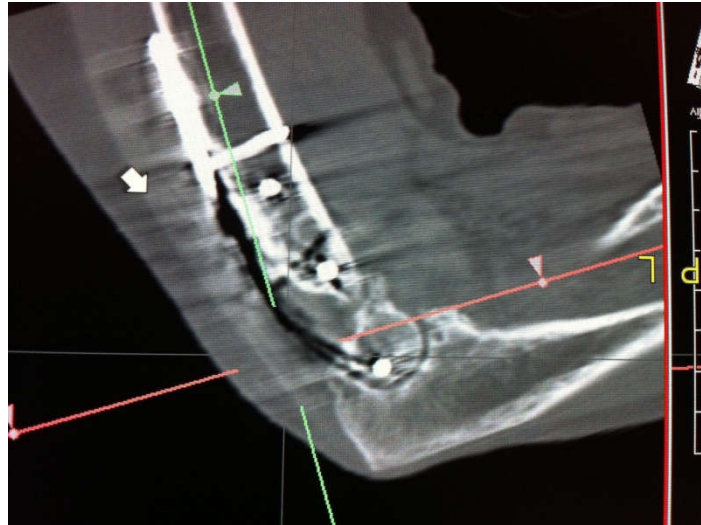- 0.625 mm

### Reformats

- Orient coronal reformats plane using an axial image at the level of the humeral condyles. Adjust coronal reformats plane to parallel the imaginary line (green line below) connecting the medial and lateral margins of the olecranon fossa.



- Orient sagittal reformats plane using the same image, perpendicular to the coronal reformats plane (blue line above).



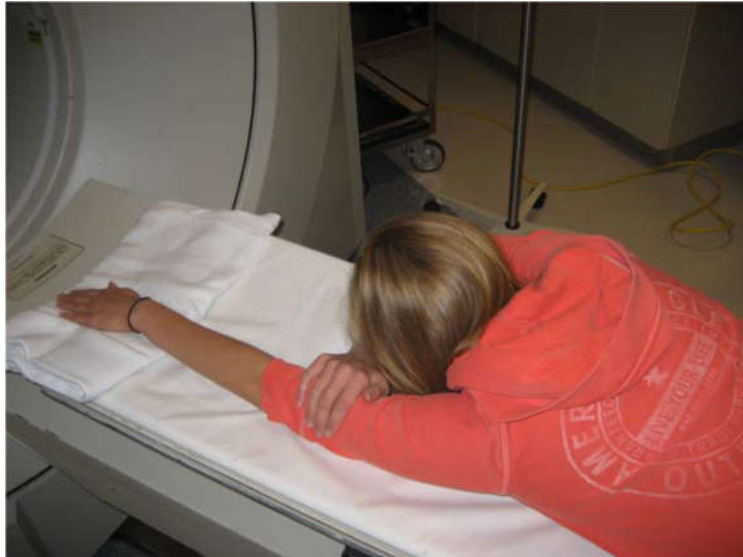**Send only these images:**

1. Scout.
2. Source axial images with bone algorithm 0.625 mm.
3. Source axial images with soft tissue algorithms 2 mm.
4. Coronal and sagittal reformats with bone algorithm 2 mm.
5. Coronal and sagittal reformats with soft tissue algorithm 2 mm.
6. 3D MIP reformats at referral's request or if you see obvious fracture.

## Routine Wrist/Hand CT

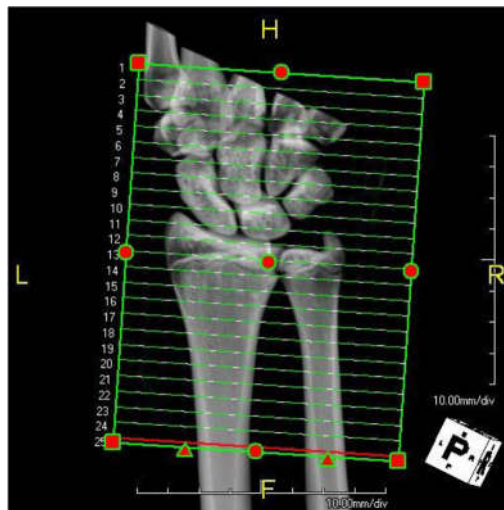
### Positioning

- Patient prone
- Arm straight above head, palm down ("Mighty Mouse" position)



### Coverage

- When scanning the **WRIST**
- From the distal radial diaphysis to the third metacarpal base.



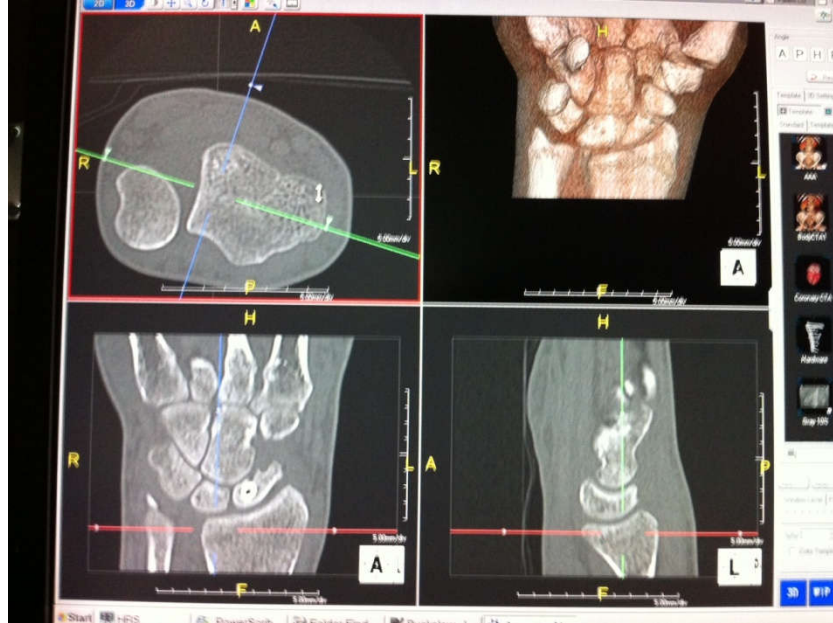
- When scanning the **HAND**
- From just proximal to the distal radioulnar joint to include the entire hand.

### Collimation

- 0.625 mm intervals
- "Small" Scanning Field of View (SFOV)
- 10-15 cm Display Field of View (DFOV)

### Reformats

- Orient coronal reformats using axial image at the distal radial epiphysis. Adjust coronal reformats plane to be perpendicular to the radial articular surface of the distal radioulnar joint (green line below, top left box).
- Orient sagittal reformats using the same image, perpendicular to the coronal reformats plane (blue line below, top left box).



**Send only these images**

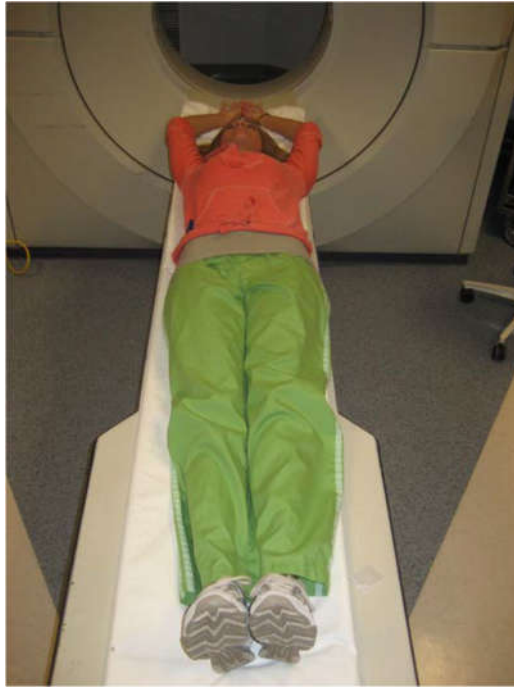
1. Scout.
2. Source axial images with bone algorithm 0.625 mm.
3. Source axial images with soft tissue algorithms 2 mm.
4. Coronal and sagittal reformats with bone algorithm 2 mm.
5. Coronal and sagittal reformats with soft tissue algorithm 2 mm.
6. 3D MIP reformats at referral's request or if you see obvious fracture.



## ROUTINE BONE PELVIS CT

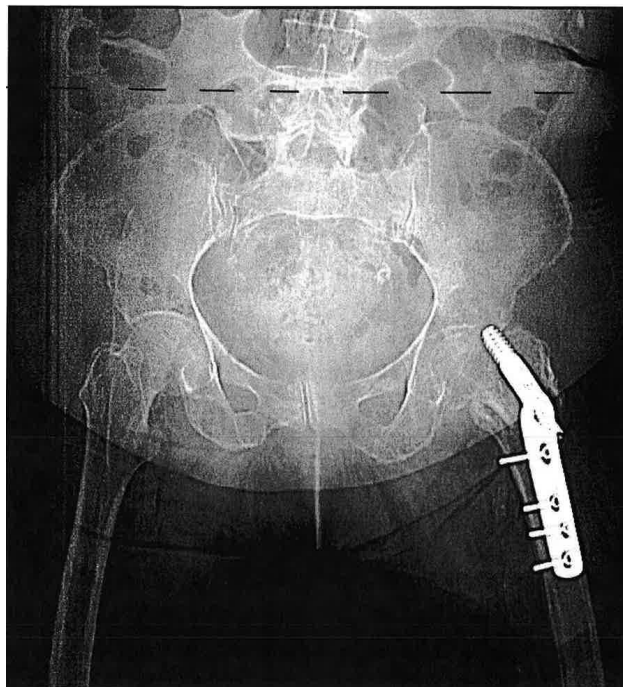
### Positioning

- Pt supine, legs flat on table, feet together. No cushions or wedges under feet or legs.



### Coverage

- From just above iliac crests to just below lesser trochanters. If hardware is present, cover the inferior most aspect of the hardware and adjacent bone.

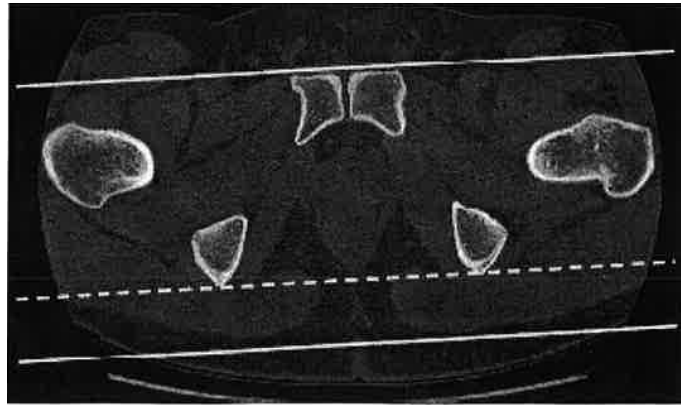


### Collimation

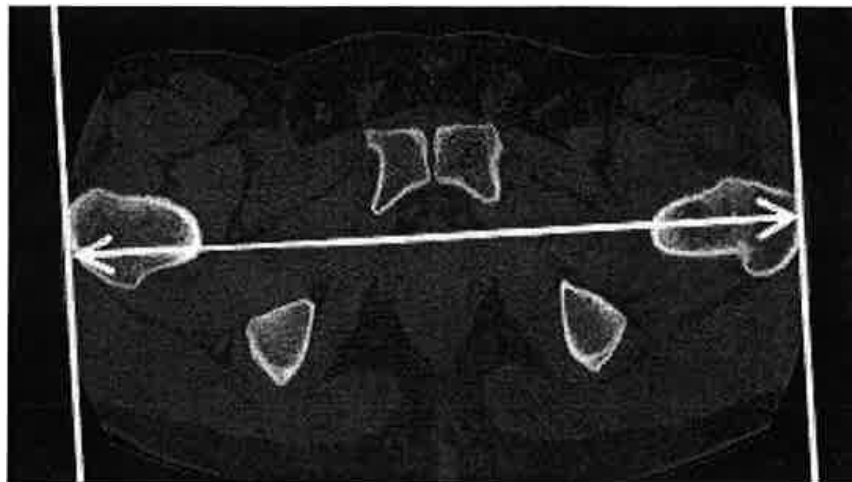
- 0.625 mm

### Reformats

- Coronal reformats are oriented using an axial image that shows the ischial tuberosities. Adjust coronal plane line (dotted line) to connect the posterior most ischial tuberosities. Cover from front of pubic symphysis to behind gluteal muscles.



- Sagittal reformats are oriented using the same axial image as above, perpendicular to the coronal reformats plane. Cover continuously from right hip to left hip including sacrum.



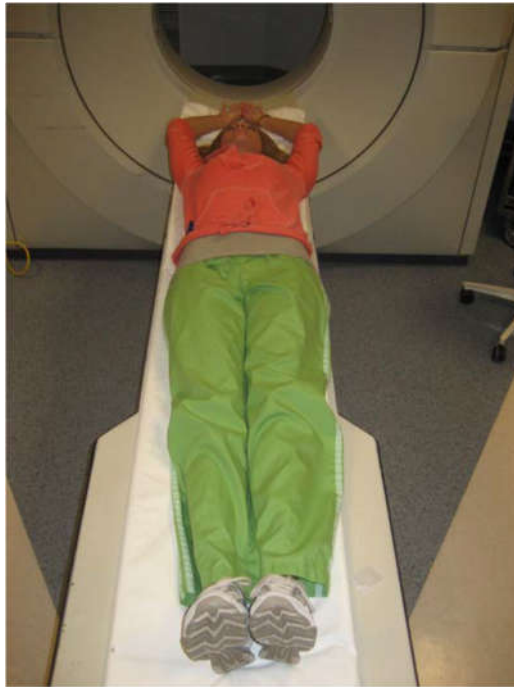
### Send only these images

1. Scout.
2. Source axial images with bone algorithm 0.625 mm.
3. Source axial images with soft tissue algorithm 2 mm.
4. Coronal and sagittal reformats of the pelvis with bone algorithm 2 mm.
5. Coronal and sagittal reformats with soft tissue algorithm 2 mm.
6. 3D MIP reformats at referral's request or if you see obvious fracture.

## ROUTINE BONE HIP CT

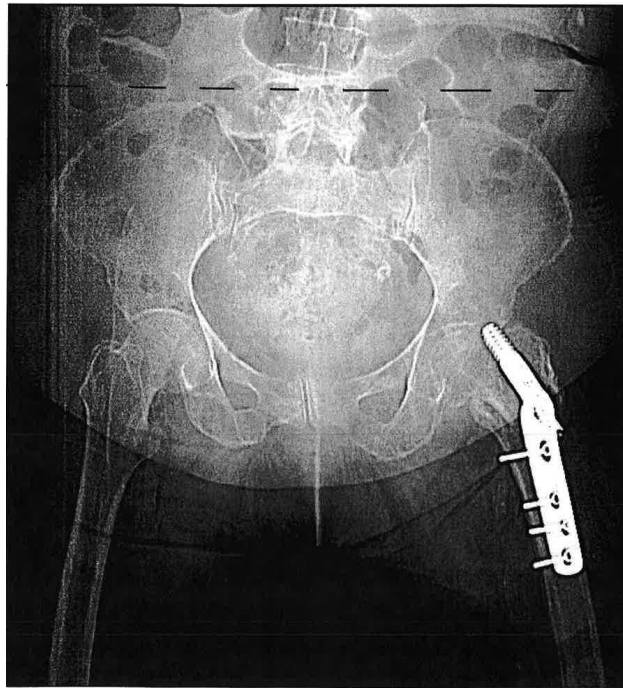
### Positioning

- Pt supine, legs flat on table, feet together. No cushions or wedges under feet or legs.



### Coverage

- From just above iliac crests to just below lesser trochanters. If hardware is present, cover the inferior most aspect of the hardware and adjacent bone.

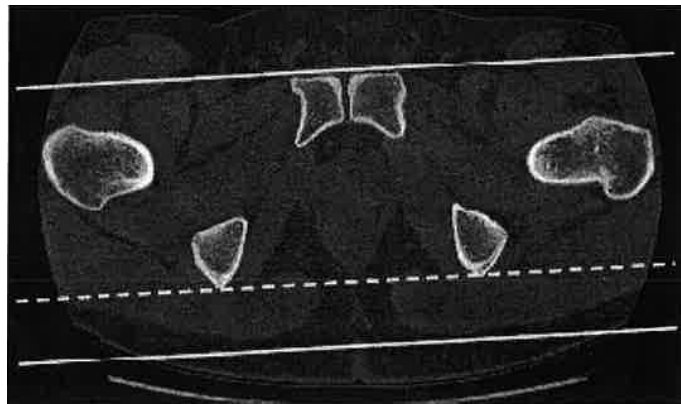


**Collimation**

- 0.625 mm

**Reformats**

- Coronal reformats are oriented using an axial image that shows the ischial tuberosities. Adjust coronal plane line (dotted line) to connect the posterior most ischial tuberosities. Cover from front of pubic symphysis to behind gluteal muscles. Collimate images to show only the hemipelvis/hip of interest.



- Sagittal reformats are oriented using the same axial image as above, perpendicular to the coronal reformats plane. Cover from the hip of interest to the mid sacrum. Collimation is 2 mm.

**Send only these images**

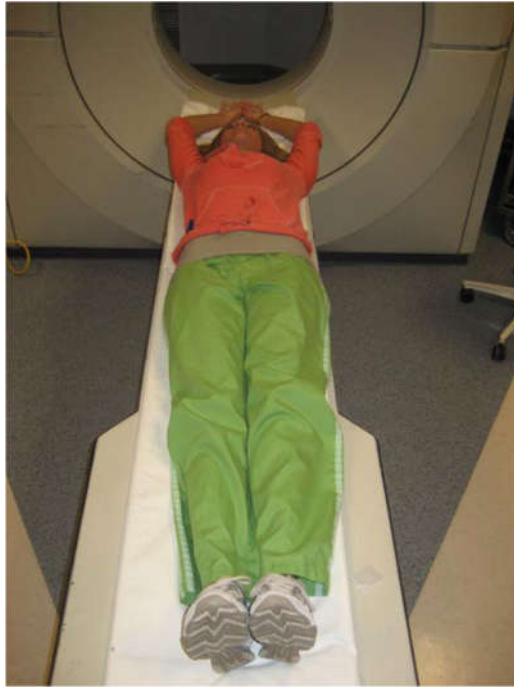
1. Scout.
2. Source pelvis axial images with bone algorithm 0.625 mm.

3. Source pelvis axial images with soft tissue algorithm 2 mm.
4. Coronal and sagittal reformats of the hemipelvis/hip of interest with bone algorithm 2 mm.
5. Coronal and sagittal reformats of the hemipelvis/hip of interest with soft tissue algorithm 2 mm.
6. 3D MIP reformats at referral's request or if you see obvious fracture.

## ROUTINE SACROILIAC CT

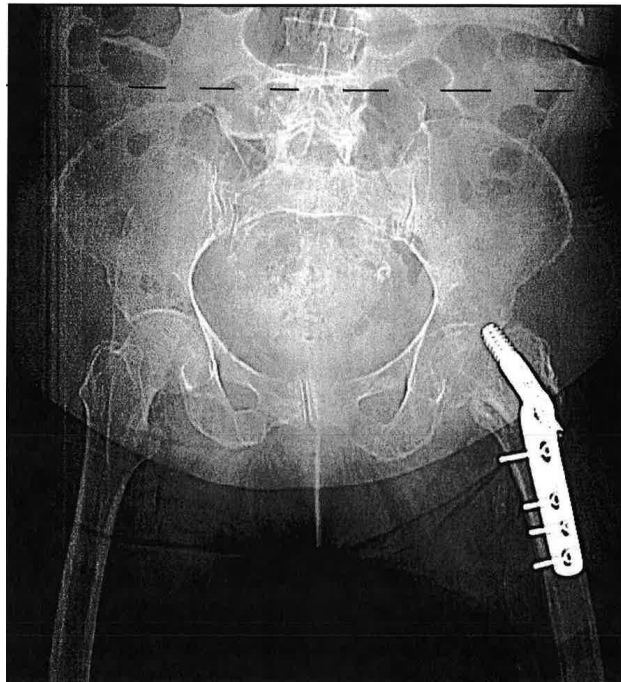
### Positioning

- Pt supine, legs flat on table, feet together. No cushions or wedges under feet or legs.



### Coverage

- From just above iliac crests to just below lesser trochanters.

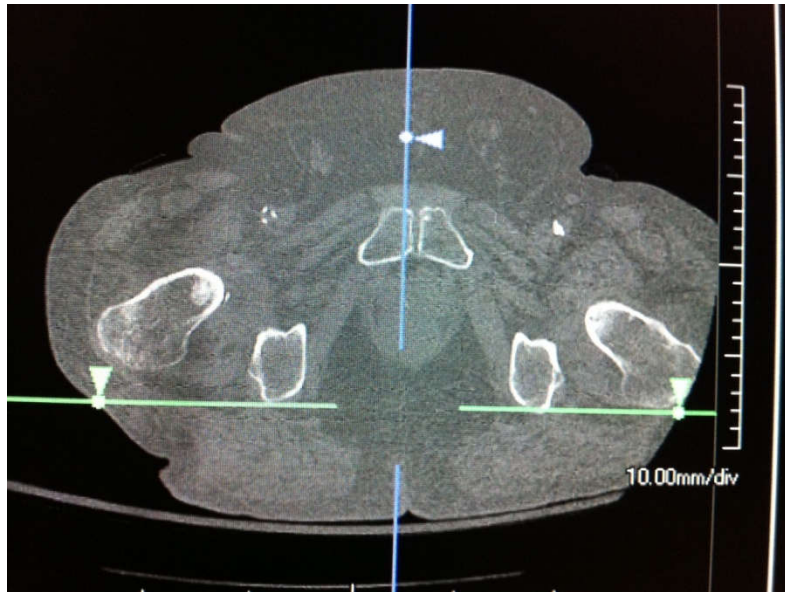

### Collimation

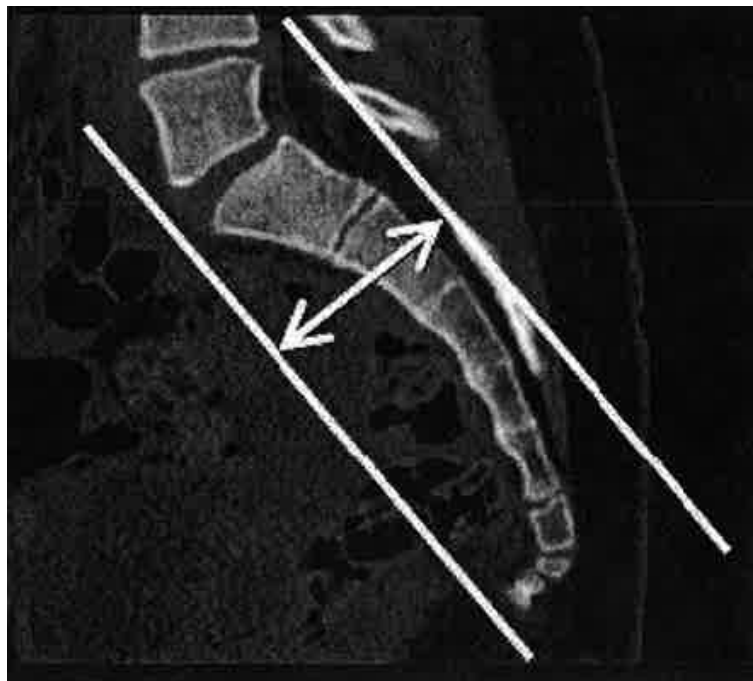- 0.625 mm

### Reformats

- Sagittal reformats are oriented using an axial image that shows the pubic symphysis. Adjust sagittal reformats plane to be parallel the pubic symphysis and to be perpendicular to the line connecting the ischial tuberosities (blue line below).



- Oblique coronal reformats are oriented using a midline sagittal image through the sacrum. Adjust oblique coronal reformats plane to parallel to the long axis of the sacrum. Cover the sacrum from front to back, including the entire SI joints. Cover SI joint to SI joint.



- Oblique axial reformats are oriented using the same midline sagittal image through the sacrum, perpendicular to the oblique coronal plane. Cover entire sacrum and coccyx. Collimation is 2 mm.

**Send only these images**

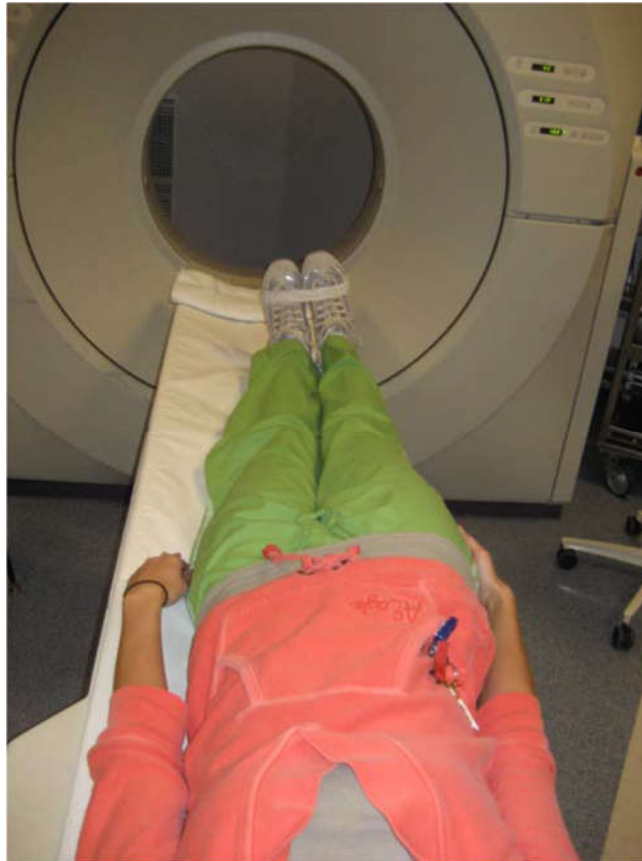1. Scout.
2. Source pelvis axial images with bone algorithm 0.625 mm.
3. Source pelvis axial images with soft tissue algorithm 2 mm.
4. Sagittal, oblique coronal and oblique axial reformats of the sacrum with bone algorithm 2 mm.
5. Sagittal, oblique coronal and oblique axial reformats of the sacrum with soft tissue algorithm 2 mm.
6. 3D MIP reformats at referral's request or if you see obvious fracture.



## ROUTINE KNEE CT

### Positioning

- Pt. supine. Slide patient over so that the knee being imaged is centered in scanner. Taping the feet together helps stabilize knees. In most cases it is fine to leave the other knee straight and within scanning field. If there is metal in the other knee, try to bend other knee so it is not in the scanning field. Plaster casts are not a problem. Scout in 2 planes.



### Coverage

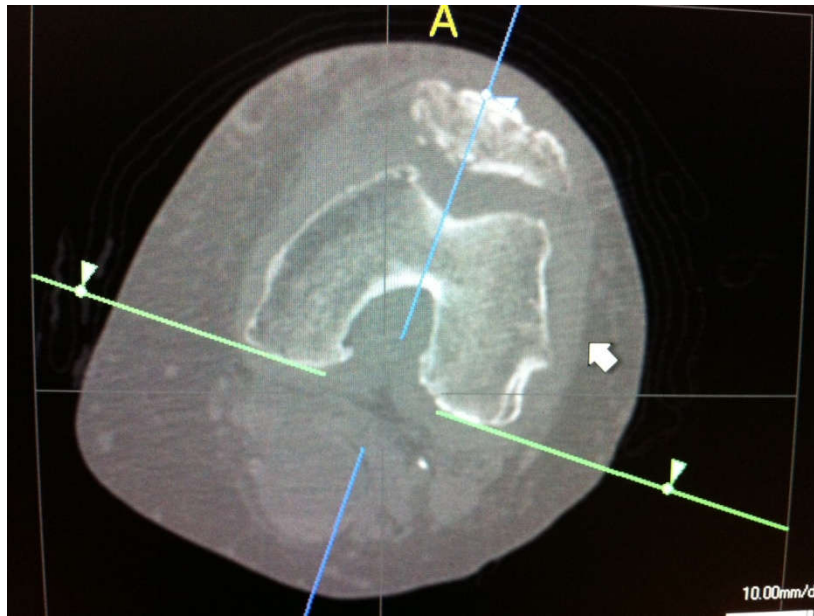
- Small FOV.
- **Side of interest only.**
- From the distal femoral metadiaphysis to the proximal tibial metadiaphysis. If scanning a metal prosthesis, cover the entire length of both the femoral and tibial components of the side of interest.

### Collimation

- Collimation is 0.625 mm

### Reformats

- Coronal reformats are oriented using axial image at the level of the femoral condyles. Adjust coronal reformats plane to parallel to the line connecting the posterior femoral condyles on the axial reformat (green line below).



- Sagittal reformats are oriented using same axial image at the level of the femoral condyles, perpendicular to the coronal reformats (blue line above).

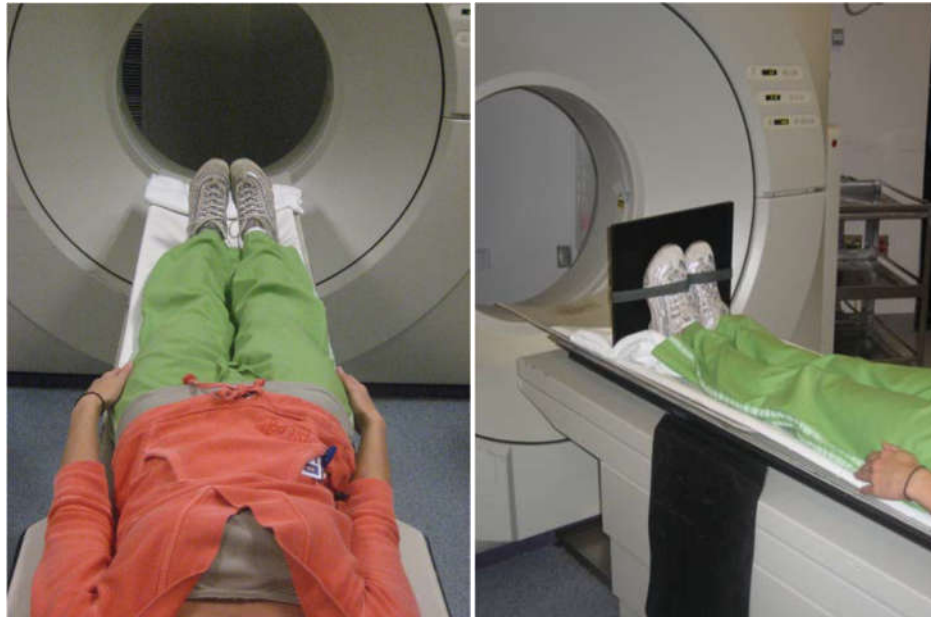**Send only these images**

1. Scout.
2. Source axial images of the requested side with bone algorithm 0.625 mm.
3. Source axial images of the requested side with soft tissue algorithm 2 mm.
4. Coronal and sagittal reformats with bone algorithm 2 mm.
5. Coronal and sagittal reformats with soft tissue algorithm 2 mm.
6. 3D MIP reformats at referral's request or if you see obvious fracture.

## ROUTINE FOOT/ANKLE/DISTAL TIBIA CT


### Positioning

- Patient supine. Feet together, centered in scanner. Toes pointing straight up. In most cases we scan both feet together. Please use foot board. If feet cannot be brought together or if the contralateral foot/ankle has hardware, position the patient such that the ankle of interest is centered in the scanner and the contralateral knee is bent with foot/ankle out of the way.



### Coverage:

- Small FOV.
- **Only side of interest.**
- Distal tibial metadiaphysis to include the whole foot.



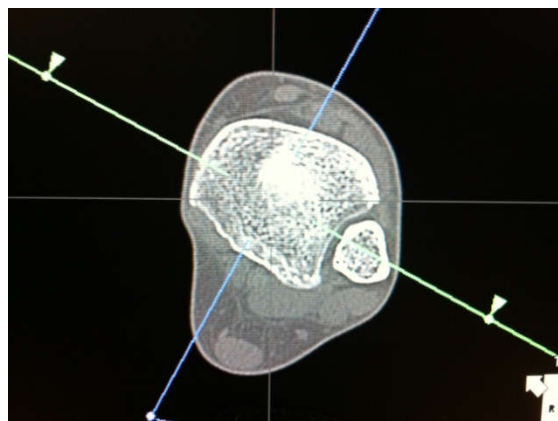
**Collimation**

- 0.625 mm

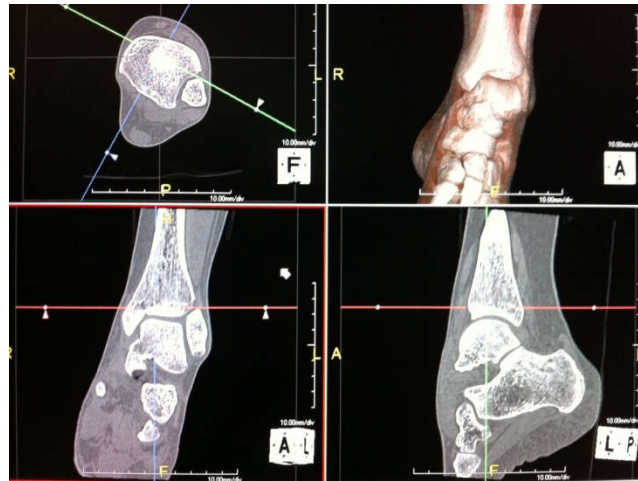
**Ankle/hindfoot:**

**Reformats**

- Orient coronal reformats using axial image at the level of the tibial fibular syndesmosis. Adjust coronal reformats plane to bisect the tibia and fibula (green line below).



- Orient the sagittal reformat plane using the same image, perpendicular to the coronal reformat plane (blue line above).



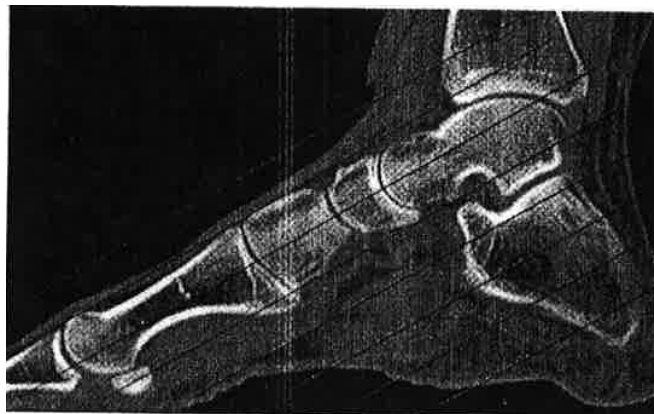**Send only these images**

1. Scout.
2. Source axial images side of interest with bone algorithm 0.625 mm.
3. Source axial images side of interest with soft tissue algorithm 2 mm.
4. Coronal and sagittal reformat side of interest with bone algorithm 2 mm.
5. Coronal and sagittal reformat with soft tissue algorithm 2 mm.
6. 3D MIP reformat at referral's request or if you see obvious fracture.

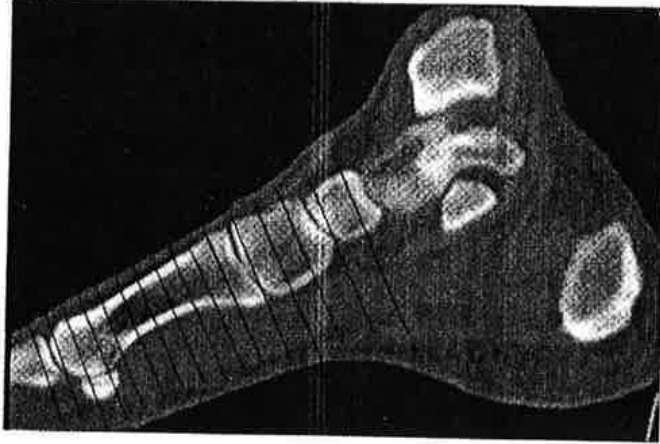
**Fore/midfoot:**

**Reformats**

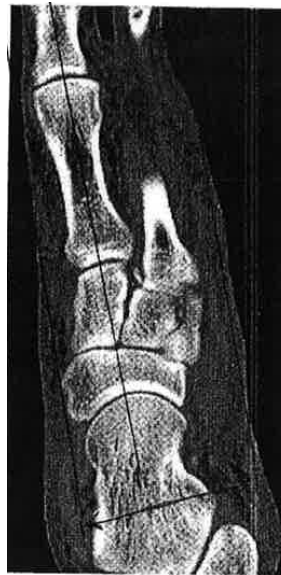- Orient axial reformat using routine reformat sagittal image that shows the entire first metatarsal (may have to oblique this image to see the entire first metatarsal). Adjust axial reformat plane to parallel the long axis of the first metatarsal.



- Orient coronal reformat using the same image, perpendicular to the axial reformat.



- Orient the sagittal reformats plane using the axial **reformat** image that shows the entire first metatarsal. Adjust the sagittal reformats plane to parallel the long axis of the first metatarsal.



**Send only these images**

1. Scout.
2. Source axial images side of interest with bone algorithm 0.625 mm.
3. Axial reformats side of interest with bone and soft tissue algorithms 2 mm.
4. Coronal and sagittal reformats side of interest with bone algorithm 2 mm.
5. Coronal and sagittal reformats side of interest with soft tissue algorithm 2 mm.
6. 3D MIP reformats at referral's request or if you see obvious fracture.

## **MSK LONG BONE/EXTREMITY CT**

(fracture, bone lesion)

### **Positioning**

- Same as the adjacent joint.

### **Coverage**

- Limit scanning field of view.
- **Only do the area and side of interest.**

### **Collimation**

- 0.625 mm

### **Reformat**

- Coronal and sagittal reformats of side of interest. If field of view center around a joint, make coronal and sagittal reformats according to orientation parameters of the adjacent joint CT as described above. Otherwise, make routine coronal and sagittal reformats.

### **Send only these images**

1. Scout.
2. Source axial images side of interest in bone algorithm 0.625 mm
3. Source axial images side of interest in soft tissue algorithm 2 mm.
4. Coronal and sagittal reformats side of interest in bone algorithm 2 mm.
5. Coronal and sagittal reformats side of interest in soft tissue algorithm 2 mm.
6. 3D MIP reformats at referral's request or if you see obvious fracture.

## **MSK SOFT TISSUE CT (use IV contrast if possible)**

(abscess, infection, mass)

### **Positioning**

- Same as the adjacent joint.

### **Coverage**

- Limit scanning field of view.
- **Only do the area and side of interest.**

### **Collimation**

- 2 mm

### **Scanning Parameters**

- 90 secs delay after intravenous contrast injection.

### **Reformat**

- Coronal and sagittal reformats of side of interest. If field of view center around a joint, make coronal and sagittal reformats according to orientation parameters of the adjacent joint CT as described above. Otherwise, make routine coronal and sagittal reformats. Collimation is 2 mm.

### **Send only these images**

1. Scout.
2. Source axial images side of interest in bone and soft tissue algorithms 2 mm.
3. Coronal and sagittal reformats side of interest in bone and soft tissue algorithm 2 mm.



## **MSK CT ARTHROGRAM**

Perform according to the joint specific protocols above.

## METAL PROTOCOL

### General Principle

- Increasing photon flux will improve the image quality; to accomplish this:
  - increase mAs
  - increase overlap
  - use higher kV
- Avoid accentuation of artifact; to accomplish this:
  - do not use a "sharpening" or "bone algorithm"
  - avoid using very thin slices
  - if possible beam should be directed along length of hardware

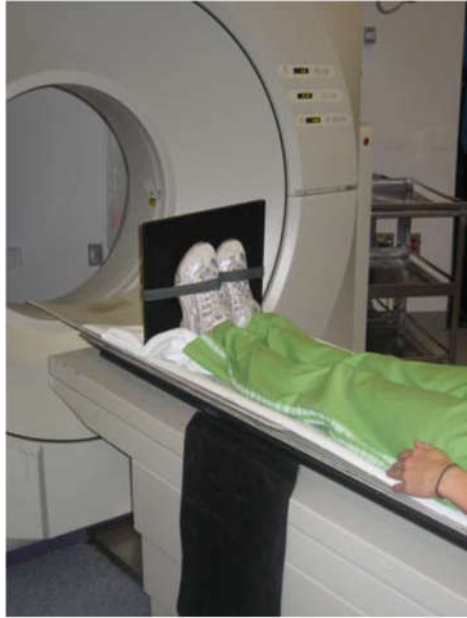Body Part	Slice Thickness (mm)	Interval (mm)	kV	mA
Large Joint	2	1	140	max
Small Joint	1.25	0.625	140	max

**Send these axial images and the soft tissue algorithm reformats** as per individual joint protocols above.

## BONE LENGTH CT SCANOGRAPH

### Positioning

- Patient supine. Feet together, centered in scanner. Toes pointing straight up. Please use foot board if available. Legs flat.



### Coverage:

- Top of pelvis to the bottom of feet.

### Send only these images

1. Scout.