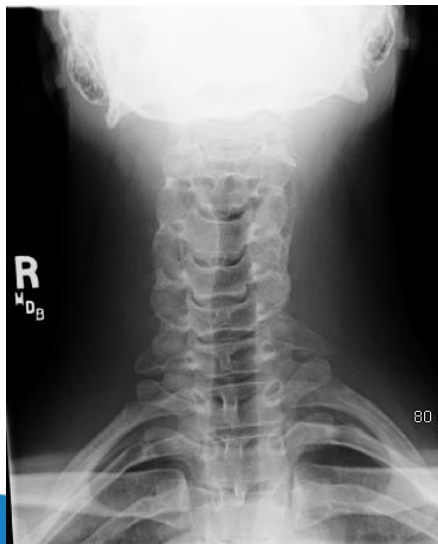
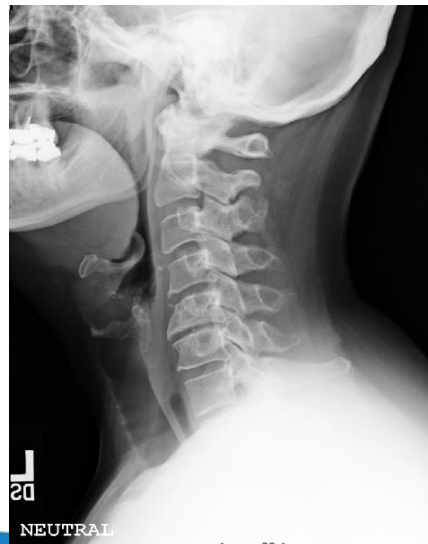
CERVICAL SPINE

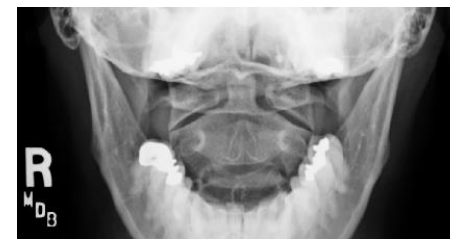
- *LATERAL, Neutral upright with 72" SID
- *SWIMMER'S VIEW, if C7-T1 joint space cannot be seen on LATERAL view
- *AP of C-2 through C-7 15° - 20° cephalic angle with mouth closed, mandible and occiput in a perpendicular line.
- *ODONTOID AP VIEW (mouth open), Fuch's if necessary
- *BILATERAL PA OBLIQUES, HEAD LATERAL , upon request
- *AP OBLIQUES may be done upright if patient is large, upon request
- *FLEXION and EXTENSION VIEWS, upon requested



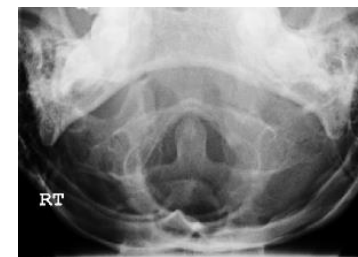AP



LATERAL



AP ODONTOID

FUCH'S
(IF NECESSARY)