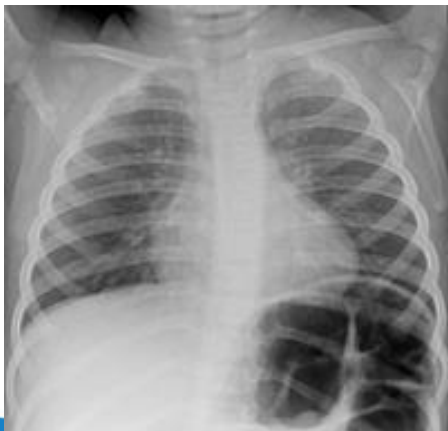

## CHEST—pregnant patients

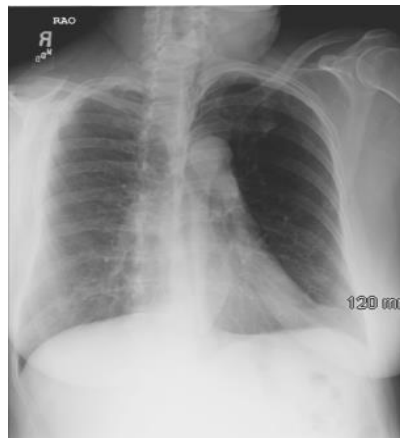PA view then show radiologist to determine if the lateral view is necessary.

### CHEST – Special Views

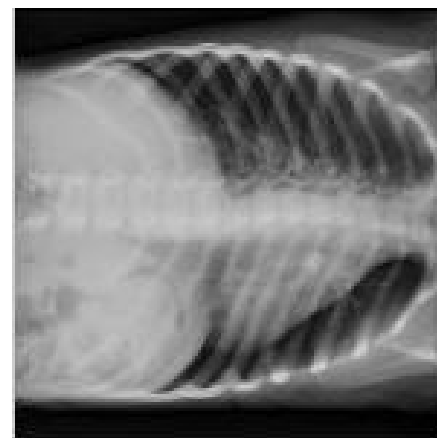
- \* LORDOTIC AND REVERSE LORDOTIC (Caudad & Cephalad angle) views as requested.
- \* FOR OBLIQUES WHEN REQUESTED - do shallow(10-15°) RAO & LAO Obliques  
The degree of obliquity may depend on the clinical situation.  
Ask the Radiologist when uncertain.
- \* Right Lateral Decubitus, right side down, as requested
- \* Left Lateral Decubitus, left side down, as requested



AP- LORDOTIC



OBL- RAO



Left Lateral Decubitus