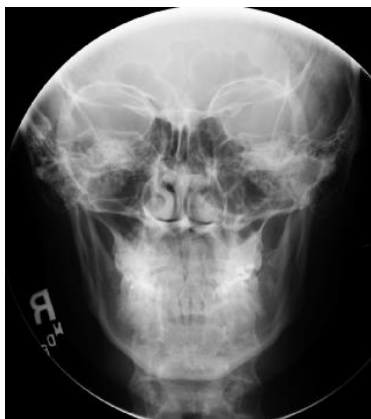
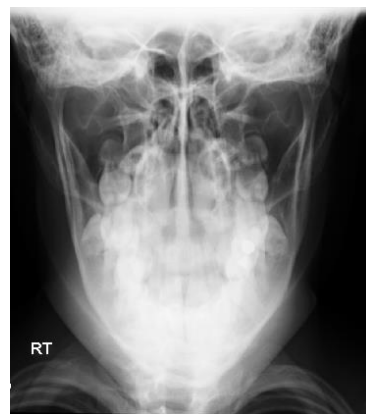
MANDIBLE

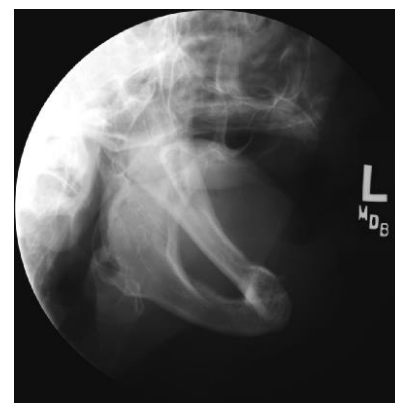- * PA, OML perpendicular to IR
- * TOWNE'S with the mouth open (9 X 9) centering on the mandible (8 X 10 lengthwise)
- * Bilateral oblique-lateral with the mouth open
- * For an anterior injury, obtain occlusal view if possible, or Cephalocaudad Tangential of Symphysis
- * For vertical ramus fractures, attempt and AP projection of the ramus through the orbit with the tube angled 10° caudad and 20° laterally, as ordered
- * Temporomandibular joint views at the Radiologist's request



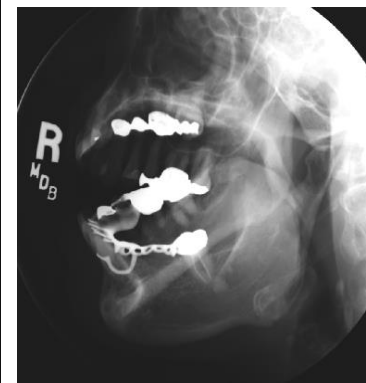
PA



TOWNE'S



AXIOLATERAL OBLIQUE



AXIOLATERAL OBLIQUE