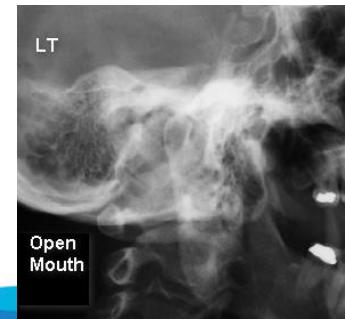
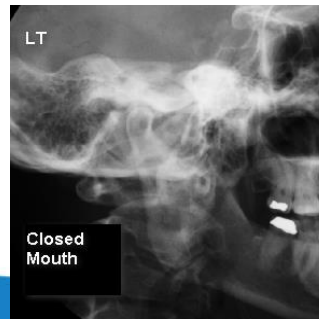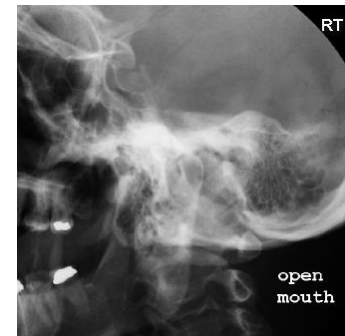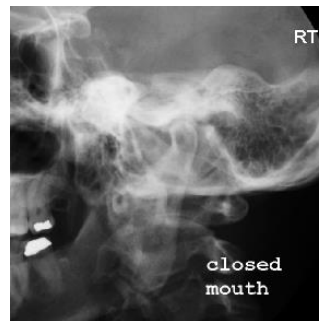


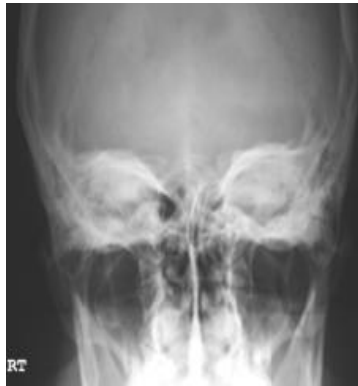TEMPOROMANDIBULAR JOINTS

- * Towne's view, centered for the mandibular condyle
- * Lateral oblique views of each side with mouth open and closed

TOMOGRAPHY – optional examination

- * If available, do bilateral lateral tomograms with mouth in open, neutral and clenched position



TMJ W/ TOMO(cont'd)

- * Open & closed mouth views of each side with the head in a Law's position (15° & 15°)
 - * Submental vertical view
 - * All views done with extension cone
- SEE MANDIBLE** for optional view of the subcondylar portion of the mandible

